

**A case of voluntary tail autotomy in the snake *Dendrophidion dendrophis*  
(Schlegel, 1837) (Reptilia: Squamata: Colubridae)**  
Um caso de autotomia voluntária de cauda da serpente *Dendrophidion dendrophis*  
(Schlegel, 1837) (Reptilia: Squamata: Colubridae)

Marinus Steven Hoogmoed<sup>1</sup>, Teresa Cristina Sauer Avila-Pires<sup>1</sup>  
<sup>1</sup>Museu Paraense Emílio Goeldi. Coordenação de Zoologia. Belém, Pará, Brasil

**Abstract:** We report direct observation of voluntary tail autotomy in the Colubrid snake *Dendrophidion dendrophis* from Monte Dourado, Pará, Brazil. Voluntary tail autotomy for this species had been reported before, but the process itself never has been described.

**Keywords:** Brazil. Amazonas. Snake. Defensive behaviour. Tail autotomy.

**Resumo:** Descrevemos uma observação direta de autotomia voluntária da cauda na serpente Colubridae *Dendrophidion dendrophis*, procedente de Monte Dourado, Pará, Brasil. Autotomia voluntária já havia sido registrada para essa espécie, porém o processo em si não havia sido descrito.

**Palavras-chave:** Brasil. Amazonas. Serpente. Comportamento defensivo. Autotomia de cauda.

---

HOOGMOED, M. S. & T. C. S. AVILA-PIRES, 2011. A case of voluntary tail autotomy in the snake *Dendrophidion dendrophis* (Schlegel, 1837) (Reptilia: Squamata: Colubridae). **Boletim do Museu Paraense Emílio Goeldi. Ciências Naturais** 6(2): 113-117.

Autor para correspondência: Marinus Steven Hoogmoed, Museu Paraense Emílio Goeldi. Coordenação de Zoologia. Av. Perimetral, 1901 – Terra Firme. Belém, PA, Brasil. CEP 66017-970 (marinus@museu-goeldi.br).

Recebido em 24/02/2011

Aprovado em 18/07/2011

Responsabilidade editorial: Hilton Tulio Costi



## INTRODUCTION

Tail autotomy in lizards is a well known and widely distributed defensive strategy, which occurs in many and diverse families (Zug *et al.*, 2001). In most instances autotomy usually is followed by regeneration of the tail, as a cartilaginous structure which is shorter than the original tail (Pianka & Vitt, 2003). In several families, like Agamidae and Varanidae, this is not the case. In these families tails only break with much effort, the wound only closes and no regeneration of the tail takes place (MSH, personal observation).

Observations on tail autotomy (urotomy) in snakes are rare. Taylor (1954), cited by Wilson (1968), noted tail autotomy in *Scaphiodontophis venustissimus* (Günther, 1894): "No. 31935, discovered under a rock, was caught by the tail, which broke off while the snake was suspended; a second time it was picked up and with little effort the snake freed itself again by breaking off another portion of the tail. A third time the experiment was tried and a third section was severed", and "On another occasion at the Esquinas Forest Preserve, a young specimen of the species was observed entering a hole. It was seized by the tail and this broke off easily, allowing the snake to escape below the root of a forest tree". We had a similar experience in July 2009, when we tried to capture a female *Thamnophis elegans* (Baird & Girard, 1853) in the Mount Timpanogos area, near Provo, Utah, U.S.A. for photographing. When grabbed and suspended by the tail, the tail broke and the snake disappeared between some rocks. No blood was evident on the severed part of the tail. Tail breakage in North-American *Thamnophis* and *Nerodia* and the African *Psammophis "phillipsii"* has been well documented (Akani *et al.*, 2002; Bowen, 2004; Fitch, 2003; Lockhart & Amiel, 2011).

Wilson (1968), acting on some remarks of Liner (1960) about the easy severance of the tail in *Pliocercus elapoides hobartsmithi* Liner, 1960, studied skeletal material of *P. e. laticollaris* Smith, 1941, *P. e. diastemus* (Bocourt, 1886) and *Scaphiodontophis zeteki nothus* Taylor & Smith, 1943 [now considered a synonym of *S. a. annulatus* (Duméril, Bibron & Duméril, 1854)] for

eventual intravertebral fracture planes in caudal vertebrae. This initial study revealed the presence of a groove in the expanded transverse processes of most but the first few caudal vertebrae in *Pliocercus*, but no other evidence of a fracture was evident. The groove was very shallow in *Scaphiodontophis*. Wilson (1968) came to the conclusion that "this grooving of the transverse processes of the caudal vertebrae of *Pliocercus* and perhaps *Scaphiodontophis* is a point of sufficient weakness that allows the vertebrae to break when the snake is seized by the tail". He was of the opinion that this adaptation would be advantageous for snakes, as in lizards that exhibit tail autotomy: attackers are stuck with the tail and the animal itself escapes. Wilson (1968) also noted that a difference with lizards is that snakes do not regenerate the damaged portion of the tail. Arnold (1984, 1988) extensively discusses tail autotomy in lizards, and Bateman & Fleming (2009) provide additional, updated information about the subject.

## RESULTS

In 2004 we executed field work in Brazilian Amazonia, in Monte Dourado, Jari River, municipality Almeirim, state of Pará, Brazil, in the context of a cooperation project between the Museu Paraense Emílio Goeldi, Belém, Pará, Brazil and the University of East Anglia, U.K. (Gardner *et al.*, 2007, 2008; Ribeiro Junior *et al.*, 2006, 2008).

During this fieldwork a specimen of *Dendrophidion dendrophis* (Schlegel, 1837) (field number MSH 7610) was collected by us on June 9, 2004 at 13:50 h in low primary forest on sandy soil, in an area known as 'Quaruba' (S 01° 1' 32" W 52° 54' 17"). It was in the shade on the forest floor on leaf litter, crossing a trail. The specimen (now MPEG 21140) was collected with intact tail and kept alive overnight, by itself, in a thin, wetted linen bag, in order to be photographed the next day.

While photographing the specimen the next day in a grass field, it was rather weary and agitated. It was observed to twist its tail and the posterior part of the body very tightly around each other, which gave

it an awkward position. All of a sudden, without being touched, the larger part of the tail broke off somewhere in part of the twisted area and the snake continued crawling away. The autotomized tail did not make any movements and neither the wound at the part attached to the body, neither the wound of the part thrown off showed extensive bleeding (a minute amount of blood was visible at both wounds, but no blood was spilled). The break occurred between subcaudal pairs 16 and 17 and did not show the characteristic conical pieces of muscle (segmented myomeres) that are present at the anterior end of recently autotomized lizard tails (Zug *et al.*, 2001; Pianka & Vitt, 2003: 76; personal observation MSH and TCSAP). The autotomized part of the tail showed a mass of muscle that fitted into a hollow area in the part of the tail attached to the body, where the ultimate scales are projecting over the end of the wound (Figure 1). The break occurred between vertebrae and at both ends of

the breaking point these are visible. The behaviour of the snake before and after autotomizing the tail did not seem different: it remained weary and agitated.

Unfortunately no pictures of the moment of shedding the tail are available, neither any detailed pictures of the twisted part of body and tail, as no such thing as a voluntary tail autotomy in a snake was expected to occur. We do have a picture that shows some of the twisting of the posterior part of the body and the tail and we reproduce it here (Figure 2).

Duellman (1978) observed that *D. dendrophis* have long tails that break readily and that most specimens in collections have incomplete tails. Martins & Oliveira (1998) observed that this species rotates the body vigorously when handled, but does not bite. They also noted that according to their unpublished data some individuals may break their tails voluntarily. Vitt (*in litt.* July 14, 2011) remarked "I've had several *Dendrophidion* autotomize their tails when

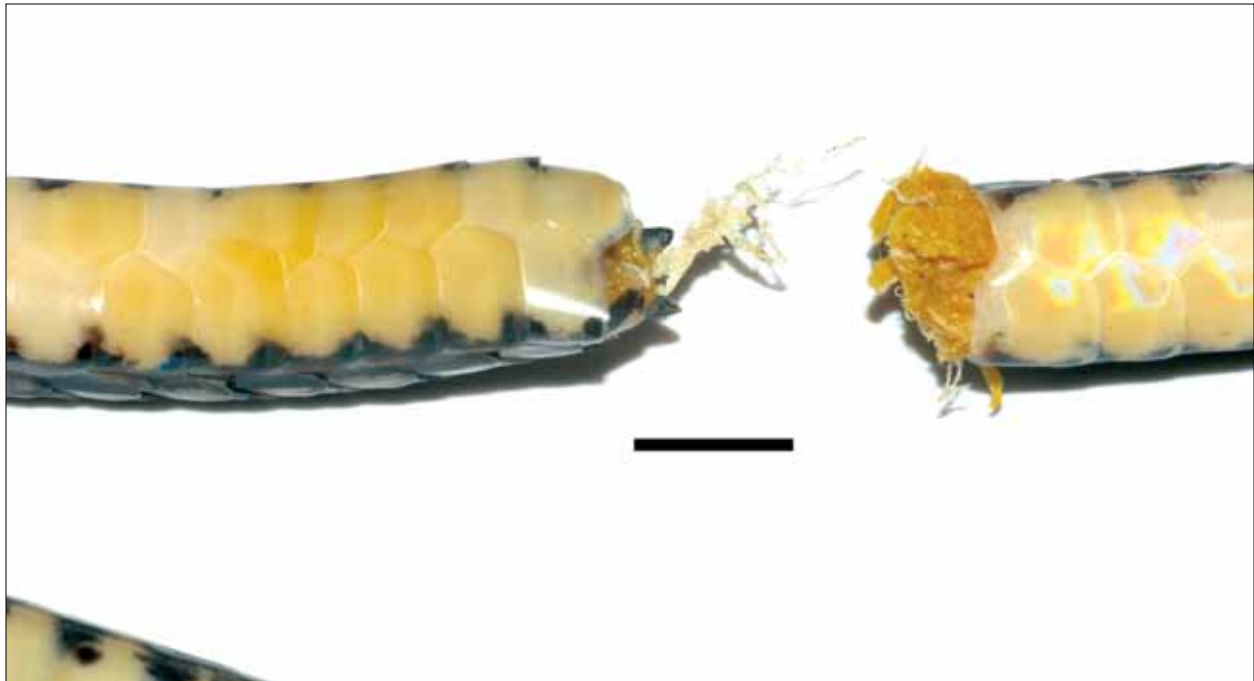


Figure 1. *Dendrophidion dendrophis* (MPEG 21140, Monte Dourado, Pará, Brazil) site of breakage of the tail photographed in preservative. Body is to the left, autotomized tail to the right. Note that no segmented myomeres are present, just an amorphous muscle mass on the anterior surface of the autotomized tail (right). On the dorsal surface of the part of the tail attached to the body (left) there is a strand of longitudinal integument that seems to run between the vertebrae and the dorsal skin. The scale represents 5 mm. Photo: A. C. M. Dourado.

I captured them". However, none of these authors do further detail those events.

## CONCLUSIONS

When counting subcaudal scales in snakes we regularly encounter snakes in which part of the tail is missing, generally only a small part near the tip, but sometimes larger parts are missing. Sometimes the break-off point has healed and shows scar tissue that neatly closes the wound. In other cases the wound looks fresh and has a similar aspect as the wound of the specimen about which we report. Until now we have assumed that these wounds were the direct effect of predation, *viz.*, that predators had bitten off or held on to part of the tail, causing it to break. However, we now start wondering whether there might be an overseen defense mechanism in (some) snakes, in which part of the tail is voluntarily thrown off, even without an external mechanical stimulus.

It would be worthwhile to be attentive to occurrences as the one described above and determine whether voluntary tail autotomy is rare, or whether this occurs more often and plays a distinct role in predator avoidance or escape in snakes.

## ACKNOWLEDGEMENTS

We want to thank Toby Gardner of the University of East Anglia, U.K. Jari project, for inviting us to visit his study sites, and for offering hospitality during our stay in Monte Dourado, Pará, Brazil. Angelo C. M. Dourado drew our attention to recent literature and made the picture of the broken tail in Figure 1.

The material was collected under collecting permits of the Ministério do Meio Ambiente issued by the Instituto Brasileiro do Meio Ambiente e dos Recursos Naturais Renováveis (IBAMA) (MMA-IBAMA, license numbers 043/2004-COMON, 0079/2004-CGFAU/LIC, 127/2005 and 048/2005).



Figure 2. *Dendrophidion dendrophis* (MPEG 21140, Monte Dourado, Pará, Brazil) with tightly twisted tail and posterior part of body, just before autotomizing part of the tail. Photo: M. S. Hoogmoed.

## REFERENCES

- AKANI, G. C., L. LUISELLI, S. M. WARIBOKO, L. UDE & F. M. ANGELICI, 2002. Frequency of tail autotomy in the African Olive Grass Snake, *Psammophis 'phillipsii'* from three habitats in southern Nigeria. **African Journal of Herpetology** 51(2): 143-146.
- ARNOLD, E. N., 1984. Evolutionary aspects of tail shedding in lizards and their relatives. **Journal of Natural History** 18: 127-169.
- ARNOLD, E. N., 1988. Caudal autotomy as a defence. In: C. GANS & R. HUEY (Eds.): **Biology of the Reptilia**: 16B: 235-273. Alan R. Liss, New York.
- BATEMAN, P. W. & P. A. FLEMING, 2009. To cut a long tail short: a review of lizard caudal autotomy studies carried out over the last 20 years. **Journal of Zoology** 277(1): 1-14.
- BOWEN, K. D., 2004. Frequency of tail breakage in the northern watersnake, *Nerodia sipedon sipedon*. **The Canadian Field-Naturalist** 118: 435-437.
- DUELLMAN, W. E., 1978. The biology of an equatorial herpetofauna in Amazonian Ecuador. **University Kansas Museum of Natural History Miscellaneous Publication** 65: 1-352.
- FITCH, H. S., 2003. Tail loss in garter snakes. **Herpetological Review** 34(3): 212-213.
- GARDNER, T. A., M. A. RIBEIRO JUNIOR, J. BARLOW, T. C. S. AVILA-PIRES, M. S. HOOGMOED & C. PERES, 2007. The value of primary, secondary and plantation forests for a neotropical herpetofauna. **Conservation Biology** 21(3): 775-787.
- GARDNER, T. A., J. BARLOW, I. S. ARAUJO, T. C. S. AVILA-PIRES, A. B. BONALDO, J. E. COSTA, M. C. ESPOSITO, L. V. FERREIRA, J. HAWES, M. I. M. HERNANDEZ, M. S. HOOGMOED, R. N. LEITE, N. F. LO-MAN-HUNG, J. R. MALCOLM, M. B. MARTINS, L. A. M. MESTRE, R. MIRANDA-SANTOS, W. L. OVERAL, L. PARRY, S. L. PETERS, M. A. RIBEIRO-JUNIOR, M. N. F. SILVA, C. SILVA MOTTA & C. A. PERES, 2008. The cost-effectiveness of biodiversity surveys in tropical forests. **Ecology Letters** 11(2): 139-150.
- LINER, E. A., 1960. A new subspecies of false coral snake (*Pliocercus elapoides*) from San Luis Potosi, Mexico. **Southwestern Naturalist** 5(4): 217-220.
- LOCKHART, J. & J. AMIEL, 2011. Natural History Notes. *Nerodia sipedon* (Northern Watersnake). Defensive behavior. **Herpetological Review** 42(2): 296-297.
- MARTINS, M. & M. E. OLIVEIRA, 1998. Natural history of snakes in forests of the Manaus region, Central Amazonia, Brazil. **Herpetological Natural History** 6(2): 78-155.
- PIANKA, E. R. & L. J. VITT, 2003. **Lizards**. Windows to the evolution of diversity: i-xiii, 1-333. University of California Press, Berkeley.
- RIBEIRO JUNIOR, M. A., T. A. GARDNER & T. C. S. AVILA-PIRES, 2006. The effectiveness of glue traps to sample lizards in a tropical rainforest. **South American Journal of Herpetology** 1(2): 131-137.
- RIBEIRO JUNIOR, M. A., T. A. GARDNER & T. C. S. AVILA-PIRES, 2008. Evaluating the effectiveness of herpetofaunal sampling techniques across a gradient of habitat change in a tropical forest landscape. **Journal of Herpetology** 42(4): 733-749.
- TAYLOR, E. H., 1954. Further studies on the serpents of Costa Rica. **University of Kansas Science Bulletin** 36 (part II) (11): 673-801.
- WILSON, L. D., 1968. A fracture plane in the caudal vertebrae of *Pliocercus elapoides* (Serpentes: Colubridae). **Journal of Herpetology** 1(1-4): 93-94.
- ZUG, G. R., L. J. VITT & J. P. CALDWELL, 2001. **Herpetology**. An introductory biology of amphibians and reptiles: i-xiv, 1-630. Academic Press, San Diego.

